

Management of Dupuytren Contracture With Ultrasound-Guided Lidocaine Injection and Needle Aponeurotomy Coupled With Osteopathic Manipulative Treatment

Steven Sampson, DO; Michael Meng, DC; Adam Schulte, OMS III; Drew Trainor, MS, OMS III; Roberto Montenegro, PhD; and Danielle Aufiero, MD

Dupuytren contracture is a debilitating disease that characteristically presents as a firm nodularity on the palmar surface of the hand with coalescing cords of soft tissue on the webs and digits. With few nonsurgical modalities providing clinical benefits, open surgical procedures are the standard of care for patients with this condition. However, recent studies have associated surgical intervention with many complications, necessitating further exploration of nonsurgical treatment options. We describe the case of a 64-year-old woman who presented with decreased extension of the fourth and fifth digits on the upper extremities bilaterally; previous conservative treatment regimens had been unsuccessful. After a diagnostic ultrasound, the patient was diagnosed as having Dupuytren contracture and underwent 5 treatments consisting of ultrasound-guided dry-needle aponeurotomy, lidocaine injections, and osteopathic manipulative treatment. During the fifth treatment session, the patient experienced dramatic relief of her symptoms after a palpable release during the manual manipulation portion of her therapeutic regimen. At 2-week follow-up, the patient was symptom-free. Based on this desirable outcome, the authors suggest future research be directed at minimally invasive therapeutic options in the management of Dupuytren contracture.

J Am Osteopath Assoc. 2011;111(2):113-116

Dupuytren contracture, first recognized in 1832 by Baron Dupuytren, has a characteristic firm nodularity on the palmar surface of the hand, with coalescing cords of soft tissue on the webs and digits, that is in clear association with the skin and dermis.¹ Shortening of the palmar fascia results in persistent flexion of the proximal interphalangeal and metacarpophalangeal joints.

While the clinical presentation of Dupuytren contracture is distinct, the underlying pathophysiology has evaded researchers during the last century. One current hypothesis involves the deposition of excess Type I collagen, contractile myofibroblast development, and increased levels of transforming growth factor- β and β -catenin.² Furthermore, genetics appear to have a role in the development of the debilitating condition, with an apparent autosomal dominant transmission and variable penetrance. However, only 10% of those who develop Dupuytren contracture have a family history of the disease.¹

The prevalence of Dupuytren contracture varies widely, ranging from 2% to 42%.³ The disease most commonly occurs in individuals with Scandinavian and Northern European ancestry.³ Men are more likely than women to develop the condition at a younger age, with a mean age of 55 years.³ Men also tend to present with more severe clinical symptoms than women.³ Patients with histories of diabetes mellitus, alcoholism, or cirrhosis appear to be at increased risk for the disease.⁴

Surgical repair of Dupuytren contracture has historically been accompanied by complications including ecchymosis and ischemia, nerve damage, and recurrence of contracture. These complications indicate a need for alternative noninvasive treatments that correct the fibrous defect. Although many nonsurgical modalities have been employed in the treatment of patients with Dupuytren contracture, including radiotherapy, dimethyl sulfoxide, and physical therapy, these conservative approaches have shown minimal clinical benefit^{5,6} and, in many circumstances, surgical intervention has been ultimately needed. Recently, however, researchers have found success in the use of *Clostridium histolyticum* collagenase injections as a noninvasive treatment option.⁵ This development demonstrates the current interest in successful alternatives to surgical intervention for the management of Dupuytren contracture.

We present a retrospective analysis of the efficacy of ultrasound guidance in the management of Dupuytren contrac-

From The Orthohealing Center in Los Angeles, California (Drs Sampson and Aufiero); San Diego Arthritis in California (Dr Meng); the Western University of Health Sciences College of Osteopathic Medicine of the Pacific in Pomona, California (Student Doctors Schulte and Trainor); and the University of Utah School of Medicine in Salt Lake City (Dr Montenegro).

Financial Disclosure: None reported.

Address correspondence to Steven Sampson, DO, The Orthohealing Center, 10780 Santa Monica Blvd Suite 440, Los Angeles, CA 90025.

E-mail: drsampson@orthohealing.com

Submitted May 14, 2010; revision received September 27, 2010; accepted October 21, 2010.

CASE REPORT

ture by needle aponeurotomy and osteopathic manipulative treatment (OMT) techniques performed while the patient was under lidocaine anesthesia. To our knowledge, this report is the first documented use of ultrasound guidance in the treatment of a patient with Dupuytren contracture. The potential advantages of using ultrasound imaging are enhanced visualization of anatomic structures; more precise needle placement, which limits surgery-related complications; and increased effectiveness of fibrous release of the fascia. Furthermore, the use of OMT may augment the effects of ultrasound-guided dry needling through physical manipulation of the muscular and fascial systems, which can decrease nodularity and increase range of motion and flexibility.⁷ Osteopathic manipulative treatment may provide more immediate, dramatic, and long-lasting results for patients with Dupuytren contracture by restoring the body's inherent motion.

Report of Case

In April 2009, a 64-year-old woman presented to an outpatient clinic in Los Angeles, California, with decreased extension of the fourth and fifth digits on the upper extremities bilaterally, with more prominent symptoms on the right hand. She reported difficulty performing her duties as a nurse as well as a decreased ability to play the piano. The patient denied decreased sensation or numbness in the hands but reported a family history that was clinically significant for a deformity similar to Dupuytren contracture. Previous treatments included physical therapy, acupuncture, symptomatic use of naproxen sodium for moderate pain, and glucosamine supplementation, all of which provided minimal to no relief. Physical examination revealed palpable fibrous nodules at the fourth and fifth metacarpophalangeal joints and proximal palmar fascia, with minor tenderness to palpation bilaterally. Increased nodularity was observed on the right hand when compared with the patient's left hand.

Because of high clinical suspicion of Dupuytren contracture, a diagnostic ultrasonography was per-

formed using the B-mode US technique on a 13.0-MHz high-frequency linear transducer (MicroMaxx; Sonosite Inc, Bothell, Washington) and color flow Doppler imaging. Ultrasonography findings revealed fascial thickening of the third, fourth, and fifth flexor tendons bilaterally, with more pronounced finger projections at the fifth digit of the right hand.

After the diagnosis of Dupuytren contracture was confirmed by results of the ultrasonography and Doppler imaging, the patient underwent a series of ultrasound-guided lidocaine injections and adjunct dry needle aponeurotomy. Immediately after the lidocaine injections and aponeurotomy, OMT, including muscle energy and myofascial release techniques, was administered to the affected tissues.

The patient received an ultrasound-guided injection of 5 mL of 1% lidocaine with a 25-gauge needle in the affected tendon sheaths and the identified fibrous bands. After injection, a 22-gauge needle aponeurotomy was performed using an in-plane needle technique, which included dry needling of fascial adhesions and nodules and hyperechoic fibers under musculoskeletal ultrasound-guidance.

Immediately after aponeurotomy, muscle energy was administered by stabilizing the proximal and distal interphalangeal joints of the affected limbs and having the patient flex her fingers against resistance. Myofascial release was also used and involved following the fascia along the area of greatest resistance and holding the tension until a palpable release was noted. All OMT techniques were directed at the long axis of tendon sheaths and palmar fascia components. The aforementioned treatment regimen of injection, aponeurotomy, muscle energy, and myofascial release was repeated once per week for 5 consecutive weeks.

Notable findings over the 5-week course of treatment were documented at the third, fourth, and fifth rounds of treatment. After the patient's third round of injections, she continued to experience decreased active range of motion in

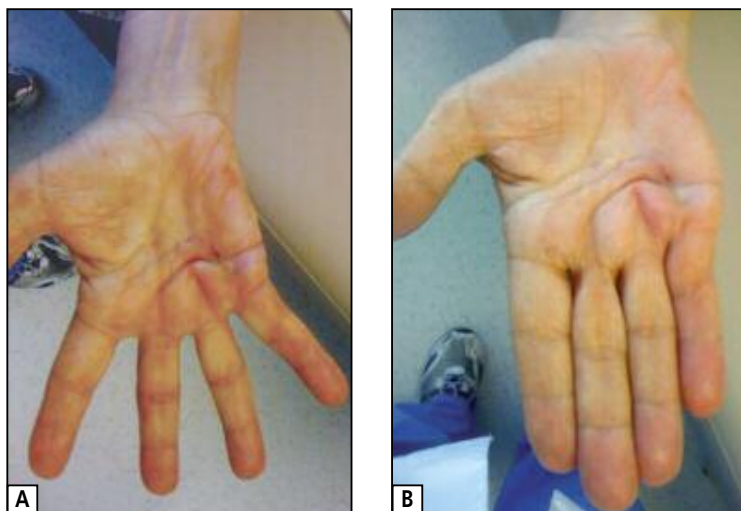


Figure 1. (A) Palmar surface of the hand of a 64-year-old woman with Dupuytren contracture immediately following the last round of treatment using needle aponeurotomy and osteopathic manipulative treatment. The image reveals slight skin dimpling 1 to 2 cm proximal to the fourth metacarpophalangeal joint and mild erythema surrounding injection site. Note that all fingers are in full extension. (B) The patient's hand 2 weeks after final treatment. Erythema and dimpling remain but have not worsened since the previous visit. The patient is still able to actively bring her fingers into full extension and normal abduction and adduction without any pain.

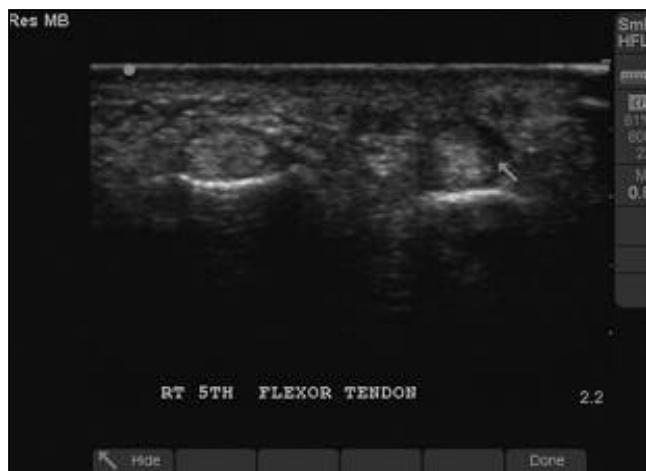

Figure 2. Ultrasound image of an affected tendon in the hand of a 64-year-old woman with Dupuytren contracture 8 weeks after completion of dry needling treatment. The image reveals a reduction in fibrous nodularity. The arrow points to a small artifact of initial nodule. Image was taken with a 13.0-MHz high-frequency linear transducer (Micromaxx; Sonosite Inc, Bothell, Washington).

the affected digits. However, with passive range of motion, she was able to achieve full extension without pain. During the fourth week of treatment, an 18-gauge needle was used for the aponeurotomy, the intention being that a larger bore needle would provide greater release of the fibrous scar tissue. At the last round of injections and manual therapy, an audible and palpable crepitus was noted during myofascial release, and the affected tendon sheaths were brought into full extension with active range of motion (Figure 1). The patient denied experiencing pain or discomfort immediately after the final treatment.

At 2-week follow-up after the final therapy session, the patient reported no swelling, pain, or stiffness and was still able to actively and fully extend the affected digits bilaterally. Most important, at an 8-week in-office follow-up, ultrasonography results showed decreased nodularity and scarring compared to ultrasonography results from the initial patient visit (Figure 2).

Comment

The current treatment option for patients with Dupuytren contracture is open needle aponeurotomy or fasciectomy, which has been shown to weaken the fibrous tissue architecture⁵ and routinely results in recurrence rates higher than those of other, less invasive treatment options.^{8,9} Furthermore, patients who experience recurrent disease are 10 times more likely to suffer complications including digital nerve and artery injury.¹⁰ Moreover, surgical intervention is associated with a

long recovery period, which often includes splint casting and physical therapy.^{11,12} Alternatively, needle aponeurotomy techniques, which have been used in Europe since the 1970s,¹³ have proven to be a safe and effective substitute to open surgical procedures. Combining needle aponeurotomy with ultrasound guidance and biphasic Doppler technology produces superior visualization of cord fibers in Dupuytren contracture, detecting structural abnormalities and allowing accurate needle placement during treatment (Figure 3). Ultrasonography is also cost effective, widely available, and easy to use in clinical practice.¹⁴

In addition, adjunct therapy with OMT likely provides greater release of the fascial tissues than would be accomplished with ultrasound-guided needle injections alone. Specifically, muscle energy techniques address the muscular tissues of the hand flexors by creating a reciprocal inhibition reflex arc that directly affects agonist muscles, presumably via activation of the peritendinous structures termed the Golgi tendon organs.¹⁵ Furthermore, to be most effective with the application of muscle energy, the physician should follow the activation and engagement of the flexor tendons, with special attention to the palmaris longus muscle. This technique is accomplished by having the patient provide direct tension through isometric contraction for 2 to 3 seconds. The patient then relaxes, and the physician brings the tendons into gentle and slow extension while carefully avoiding rebound flexion. This series of movements should be repeated 3 to 5 times to allow greater resting muscle length and to provide greater extension (Figure 4).¹⁶

Direct myofascial release should be administered immediately after muscle energy. This treatment protocol provides maximum correction of the fascia contracture by engaging the restrictive barriers of the palmar fascia with continuous palpatory feedback to achieve free movement of the tissues.¹⁵ Myofascial pain syndrome of the palmaris longus muscle may

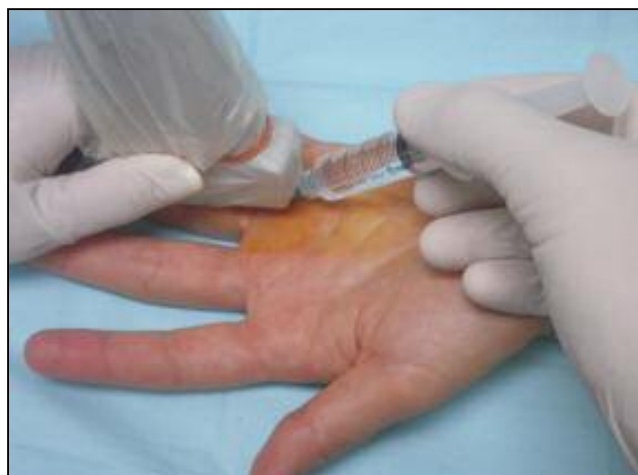

Figure 3. Lidocaine injection technique with dry needling using ultrasound guidance to optimize visualization of cord tissue.

CASE REPORT

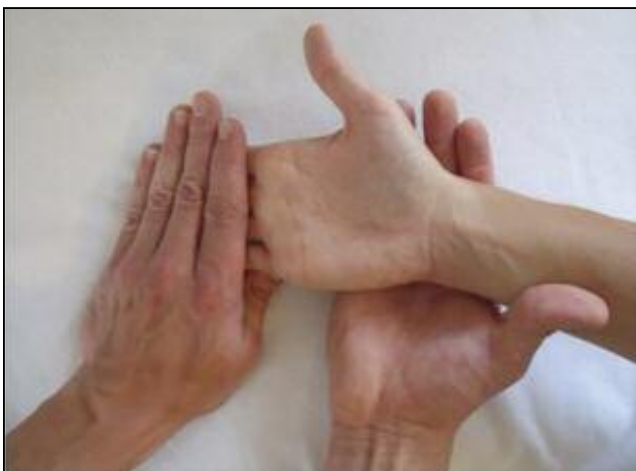

Figure 4. The application of muscle energy technique. The physician stabilizes the proximal and distal interphalangeal joints as the patient performs an isometric contraction at the metacarpophalangeal joints. The contraction is held 2 to 3 seconds and is repeated 3 to 5 times for maximal lengthening effect.

be addressed by targeting and inactivating the trigger points within the muscle itself with prolonged ischemic pressure, needle injection of the triggers, and stretch and spray techniques.¹⁸ Cumulatively, these factors support the use of ultrasound-guided dry-needle aponeurotomy in conjunction with ultrasound-guided lidocaine injections and OMT as potential alternatives to open surgical aponeurotomy or fasciectomy.

Conclusion

Our case report of a patient with Dupuytren contracture who experienced immediate and complete resolution of her symptoms with minimally invasive therapy demonstrates exciting possibilities for management of this disease. Ultrasound-guided dry needle aponeurotomy and OMT under lidocaine analgesia should be considered as an alternative to open needle surgical aponeurotomy or fasciectomy. The suggested clinical efficacy of this protocol, along with its cost effectiveness, availability, ease of use, and decreased risk for potential complications, warrants further research and consideration in the treatment of patients with Dupuytren contracture.

References

1. Hunt TR 3rd. What is appropriate treatment for Dupuytren contracture? *Cleve Clin J Med*. 2003;70(2):96-97. <http://www.cjcm.org/content/70/2/96.full.pdf>. Accessed January 13, 2011.
2. Vi L, Njarlangattil A, Wu Y, Gan BS, O'Gorman DB. Type-1 collagen differentially alters β -catenin accumulation in primary Dupuytren's disease cord and adjacent palmar fascia cells. *BMC Musculoskelet Disord*. 2009;10:72. doi:10.1186/1471-2474-10-72.
3. Townley WA, Baker R, Sheppard N, Grobbelaar AO. Dupuytren's contracture unfolded. *BMJ*. 2006;332(7538):397-400.

4. Prosser R, Conolly WB. Complications following surgical treatment for Dupuytren's contracture. *J Hand Ther*. 1996;9(4):344-348.
5. Starkweather KD, Lattuga S, Hurst LC, Badalamente MA, Guilak F, Sampson SP, Dowd A, Wisch D. Collagenase in the treatment of Dupuytren's disease: an in vitro study. *J Hand Surg Am*. 1996;21(3):490-495.
6. Hurst LC, Badalamente MA. Nonoperative treatment of Dupuytren's disease. *Hand Clin*. 1999;15(1):97-107, vii.
7. DiGiovanna EL. Chapter 1: introduction. In: DiGiovanna EL, Schiowitz S, Dowling DJ. *An Osteopathic Approach to Diagnosis and Treatment*. 3rd ed. Philadelphia, PA: Lippincott Williams & Wilkins; 2005:1-4.
8. Prosser R, Conolly WB. Complications following surgical treatment for Dupuytren contracture. *J Hand Ther*. 1996;9(4):344-348.
9. Dias JJ, Braybrooke J. Dupuytren's contracture: an audit of the outcomes of surgery. *J Hand Surg Br*. 2006;31(5):514-521.
10. Denkler K. Surgical complications associated with fasciectomy for Dupuytren's disease: a 20-year review of the English literature. *Eplasty*. 2010;10:e15. <http://www.ncbi.nlm.nih.gov/pmc/articles/PMC2828055/pdf/eplasty10e15.pdf>. Accessed January 13, 2011.
11. Larson D, Jerosch-Herold C. Clinical effectiveness of post-operative splinting after surgical release of Dupuytren's contracture: a systematic review. *BMC Musculoskelet Disord*. 2008;9:104. doi:10.1186/1471-2474-9-104.
12. Bayat A, McGrouther DA. Management of Dupuytren's disease—clear advice for an elusive condition [review]. *Ann R Coll Surg Engl*. 2006;88(1):3-8. doi:10.1308/003588406X83104
13. Webb JA, Stothard J. Cost minimisation using clinic-based treatment for common hand conditions—a prospective economic analysis. *Ann R Coll Surg Engl*. 2009;91(2):135-139.
14. Martinoli C, Bianchi S, Dahmane M, Pugliese F, Bianchi-Zamorani MP, Valle M. Ultrasound of tendons and nerves. *Eur Radiol*. 2002;12(1):44-55.
15. Ehrenfeuchter WC, Sandhouse M. Muscle energy techniques. In: Ward RC, ed. *Foundations for Osteopathic Medicine*. 2nd ed. Philadelphia, PA: Lippincott Williams & Wilkins; 2003:881-884.
16. Chila AG. Fascial-ligamentous release: indirect approach. In: Ward RC, ed. *Foundations for Osteopathic Medicine*. 2nd ed. Philadelphia, PA: Lippincott Williams & Wilkins; 2003:908-910.
17. Greenman PE. *Principles of Manual Medicine*. 2nd ed. Philadelphia, PA: Lippincott Williams & Wilkins; 1996:399-409.
18. Simons DG, Travell JG, Simons LS. Palmaris longus. In: Travell JG, Simons DG. *Travell & Simons' Myofascial Pain and Dysfunction: The Trigger Point Manual*. 2nd ed. Baltimore, MD: Lippincott Williams & Wilkins; 1999:523-530. Upper Half of Body; vol 1.