

Osteopathic Manipulative Medicine for Carpal Tunnel Syndrome

Gilbert Siu, DO, PhD; J. Douglas Jaffe, DO; Maryum Rafique, DO, MA; and Michael M. Weinik, DO, MS

Carpal tunnel syndrome (CTS) is 1 of the most common peripheral nerve entrapment disorders. Osteopathic manipulative medicine can be invaluable in diagnosing and managing CTS. Combined with a patient's history and a standard physical examination, an osteopathic structural examination can facilitate localizing the nerve entrapment, diagnosing CTS, and monitoring the disease process. Osteopathic manipulative treatment is non-invasive and can be used to supplement traditional CTS treatment methods. The authors also review the relevant anatomy involving CTS and the clinical efficacy of osteopathic manipulative medicine in the management of this disorder.

J Am Osteopath Assoc. 2012;112(3):127-139

Carpal tunnel syndrome (CTS) is 1 of the most common peripheral nerve entrapment disorders in the United States that has impacted health care expenditures in terms of both dollars and productivity.¹⁻³ This syndrome is estimated to affect 3% to 6% of US adults, with 3 times as many women affected as men.^{4,5} Although a thorough patient history and a standard physical examination are important in the diagnosis of CTS, the application of osteopathic manipulative medicine (OMM), including an osteo-

pathic structural examination and osteopathic manipulative treatment (OMT), can be invaluable in diagnosing and managing CTS.

On the basis of our experience, OMM is underused in the treatment of patients with CTS. We review the key elements of an osteopathic approach to CTS, including relevant anatomy, osteopathic structural examination, current diagnostic criteria, treatment modalities, and clinical efficacy.

Anatomy of the Carpal Tunnel

The carpal tunnel is bound by several relatively inelastic components. The transverse carpal ligament (TCL), or flexor retinaculum, is a heavy band of fibers that runs between the hamate and pisiform bones medially to the scaphoid and trapezium bones laterally. It forms a fibrous sheath, which binds the carpal tunnel anteriorly and creates a fibro-osseous tunnel (*Figure 1*).⁶ The posterior aspect of the tunnel is bordered by carpal bones. The median nerve and finger flexor tendons that originate from the flexor digitorum superficialis, flexor digitorum profundus, and flexor pollicis longus course through the carpal tunnel from the forearm to the hand (*Figure 2*). The carpal tunnel is narrowest at the level of the hook of the hamate, where the tunnel averages 20 mm in width.⁶ The TCL ranges from 1.5 to 6 mm in thickness and is up to 21.7 mm in length.⁶ The TCL is almost constantly tensed and helps maintain the carpal arch, which is a distensible structure that serves as a retinacular pulley for the flexor tendons.

Causes and Signs

The causes of CTS are multifactorial and can be classified as anatomic, occupational, and systemic (*Figure 3*).^{7,8}

Changes in the carpal tunnel anatomy can lead to elevation in carpal tunnel pressure and compression of the median nerve.⁹ For example, a lunate dislocation can narrow the carpal tunnel and result in increased carpal tunnel pressure, which ultimately causes CTS.¹⁰ In addition, a ganglion cyst can occupy space in the carpal tunnel, resulting in compression of the median nerve and increased pressure in the carpal tunnel.¹¹

Tissue pressure in the carpal tunnel normally ranges from 2 to 31 mm Hg, dependent on wrist position. In patients with CTS, tissue pressure is elevated, ranging

From the Department of Rehabilitation Medicine at the University of Medicine and Dentistry of New Jersey-School of Osteopathic Medicine in Stratford and HealthSouth Rehabilitation Hospital of Vineland in New Jersey (Dr Siu); the Department of Anesthesiology at Wake Forest Baptist Hospital in Winston-Salem, North Carolina (Dr Jaffe); the Department of Physical Medicine and Rehabilitation at Temple University Hospital in Philadelphia, Pennsylvania (Drs Rafique and Weinik); and MossRehab in Philadelphia, Pennsylvania (Dr Rafique).

Financial Disclosures: None reported.

Address correspondence to Gilbert Siu, DO, PhD, Assistant Professor/Medical Director, University of Medicine and Dentistry of New Jersey-School of Osteopathic Medicine and HealthSouth, 42 E Laurel Rd - UDP3900, Stratford, NJ 08084-1354.

E-mail: gilbert.siu@gmail.com

Submitted July 11, 2011; final revision received November 13, 2011; accepted November 14, 2011.

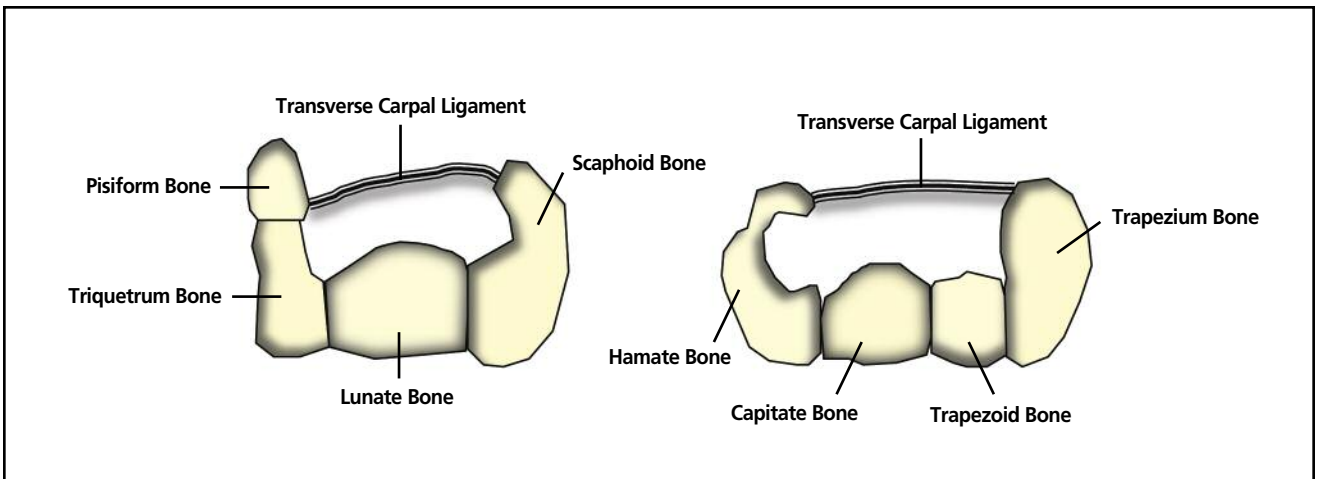


Figure 1. Transverse carpal ligament (flexor retinaculum) as it runs between the hamate bone and pisiform bone medially to the scaphoid bone and trapezium bone laterally.

from 32 to 110 mm Hg. Physiologically, increased carpal tunnel pressure is generated by wrist flexion and extension, as well as digit flexion.^{9,12} Likely for this reason, the most common cause of CTS is repetitive occupational stress injury to the wrist with resultant flexor tenosynovitis.^{13,14}

Multiple pathologic states can also result in increased carpal tunnel pressure, including rheumatoid arthritis, pregnancy, and diabetes. Pathologic analysis of CTS tissue samples from patients with flexor tenosynovitis reveals edema and thickening of blood vessel walls within the endoneurium and perineurium, fibrosis, myelin thinning, and nerve fibers in various stages of degeneration and regeneration.^{15,16} Patients with amyloidosis present with localized amyloid deposition in the tenosynovium and

transverse carpal ligament.^{15,16} These pathologic conditions can lead to neuropraxia (conduction block) due to the demyelination, resulting in loss of conduction of the nerve distal to the compression. Median nerve compression at the wrist can lead to ischemia, intraneural blood flow disruption, and impaired axonal transport.¹⁷ The compression can also cause axonal injury (ie, Wallerian degeneration), in which the axon degenerates distal to the lesion and leads to CTS symptoms.^{18,19}

Symptoms

The patient's history is 1 of the most important elements in diagnosing CTS. Patients with CTS classically report burning pain, numbness, and paresthesia in the hands, typically in

the distribution of the median nerve and most often in the thumb and first 2 ½ digits (Figure 4). However, symptoms can radiate to the entire hand, forearm, elbow, and even as far as the shoulder (ie, Valleix phenomenon).²⁰ Symptoms usually present after periods of repetitive motion that involve the hand, wrist, or both, especially after motions that involve forceful gripping. Symptoms typically worsen at night; the wrist innately flexes during sleep, which will often lead to sleep disturbances secondary to paresthesia and pain. Patients with CTS experience diminished grip strength and thenar muscle atrophy as the disease progresses. Importantly, some patients have anatomic variants,

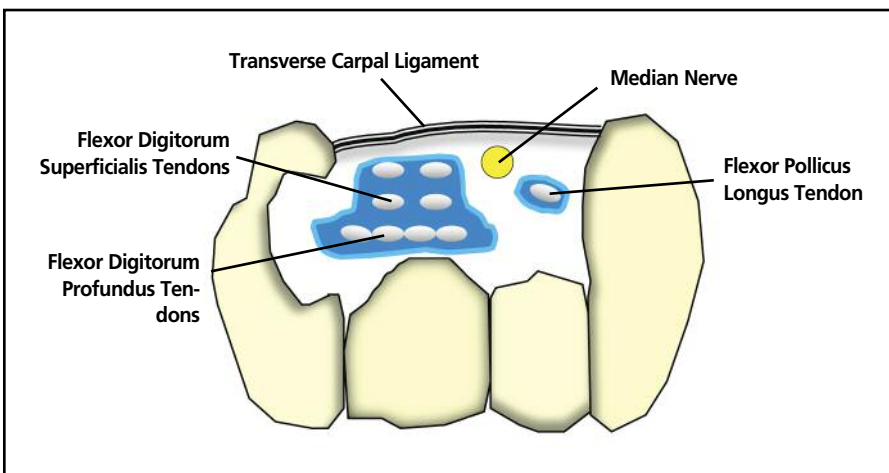


Figure 2. Cross-sectional anatomy of the carpal tunnel. The carpal tunnel consists of the flexor retinaculum (transverse carpal ligament) and the structures passing through it (ie, flexor digitorum profundus tendons, flexor digitorum superficialis tendons, flexor pollicis longus tendon, and median nerve).

Anatomic
Dislocation of the lunate
Recent or malhealed fracture
Multiple myeloma
Anomalous flexor tendons
Lipoma
Ganglionic cysts
Congenital small carpal canal
Proximal lumbrical muscle insertion anomaly
Radial artery thrombosis
Occupational
Repetitive stress injury leading to flexor tenosynovitis
Hand-arm vibration syndrome
Systemic
Myxedema
Amyloidosis
Sarcoidosis
Leukemia
Hemochromatosis
Diabetes
Pregnancy
Congestive heart failure
Rheumatoid arthritis
Acromegaly
Hyperparathyroidism
Eosinophilic fasciitis
Obesity
Lyme disease

Figure 3. Causes of carpal tunnel syndrome.

such as Riche-Cannieu and Martin-Gruber anastomoses (the later of which is present in 10% to 44% of the population). These patients will present with variable paresthetic locations.²¹⁻²³

Examination

After the patient's history is established, the physical examination will often reveal classic clinical signs of CTS. The primary and most widely used provocative clinical tests to examine for median nerve compression at the wrist are the Phalen test and the elicitation of a Tinel sign. The Phalen test is performed by having the patient flex his or her wrist at 90° and then having the patient maintain this position for 1 minute or until pain and paresthesia are reproduced.^{24,25} The test for a Tinel sign is performed with ballottement over the carpal tunnel. A positive result is noted if similar clinical symptoms are reproduced.²⁴ However, the sensitivity and specificity of these tests are relatively low, with sensitivity ranging from 60% to 75% and specificity ranging from 47% to 67%.²⁶

In addition to these tests, Katz et al²⁷ proposed that a symptom diagram can assist in the diagnosis of CTS; using this diagnostic tool, patients identify areas of pain, numbness, paresthesia, and hypoesthesia on an illustrated rep-

resentation of hand surface anatomy. This instrument yielded a sensitivity of 96% and a specificity of 76% for the diagnosis of CTS.

Sensory and Nerve Testing

Sensory testing such as light touch, pinprick, 2-point discrimination, monofilament, and vibration testing can be used to screen for CTS; however, these tests yield more conclusive results when the disease process is more advanced. Diminished sensation to light touch and pinprick are present in median nerve distribution, sparing the ulnar and radial nerves (Figure 4). Additionally, specific manual muscle testing of the abductor pollicis brevis muscle and the first digit of the flexor digitorum profundus muscles provides localization of the lesion because these muscles are innervated by the median nerve past the carpal tunnel. However, some of these findings may lack diagnostic value.²⁸ For instance, distribution of abductor pollicis brevis muscle atrophy has a high specificity (>90%) but low sensitivity (<25%).²⁹

The consensus committees from the American Academy of Neurology, the American Association of Electrodiagnostic Medicine, and the American Academy of Physical Medicine and Rehabilitation recognize nerve conduction studies as the diagnostic standard for carpal tunnel syndrome.³⁰⁻³² These tests include nerve conduction studies and electromyography, which help confirm the diagnosis of CTS and localize nerve entrapment. These studies have an 85% sensitivity and a specificity greater than 95%, although nerve conduction studies have a low false-negative rate.³²⁻³⁴ Although electrodiagnostic studies provide diagnostic confirmation for CTS, these studies also measure the severity of the damage and the extent of demyelination of the median nerve. These measurements allow grading of CTS and give the physician indications for conservative vs nonconservative treatments. The study results can also rule out causes of the hand symptoms other than CTS, such as pronator teres syndrome, cervical radiculopathy, polyneuropathy, and brachial plexopathy.

Imaging

Currently, no specific laboratory or imaging study is used to diagnose CTS. Screening for hypothyroidism and diabetes in all patients with CTS is inexpensive and recommended.³⁵ Radiography of the hand and wrist is of little diagnostic value; thus its expense is unjustified unless dislocation of the lunate bone, bone fracture, or severe arthritis is clinically suspected.³⁶ Magnetic resonance imaging and musculoskeletal ultrasonography may reveal anatomic as well as chemical disturbances evidenced by edema, flattening of the median nerve, narrowing of the carpal tunnel, loss of normal adipose tissue in the carpal tunnel, and postsurgical changes such as scar formation.³⁷⁻³⁸ Recent studies³⁹⁻⁴¹ have shown promise in using musculoskeletal

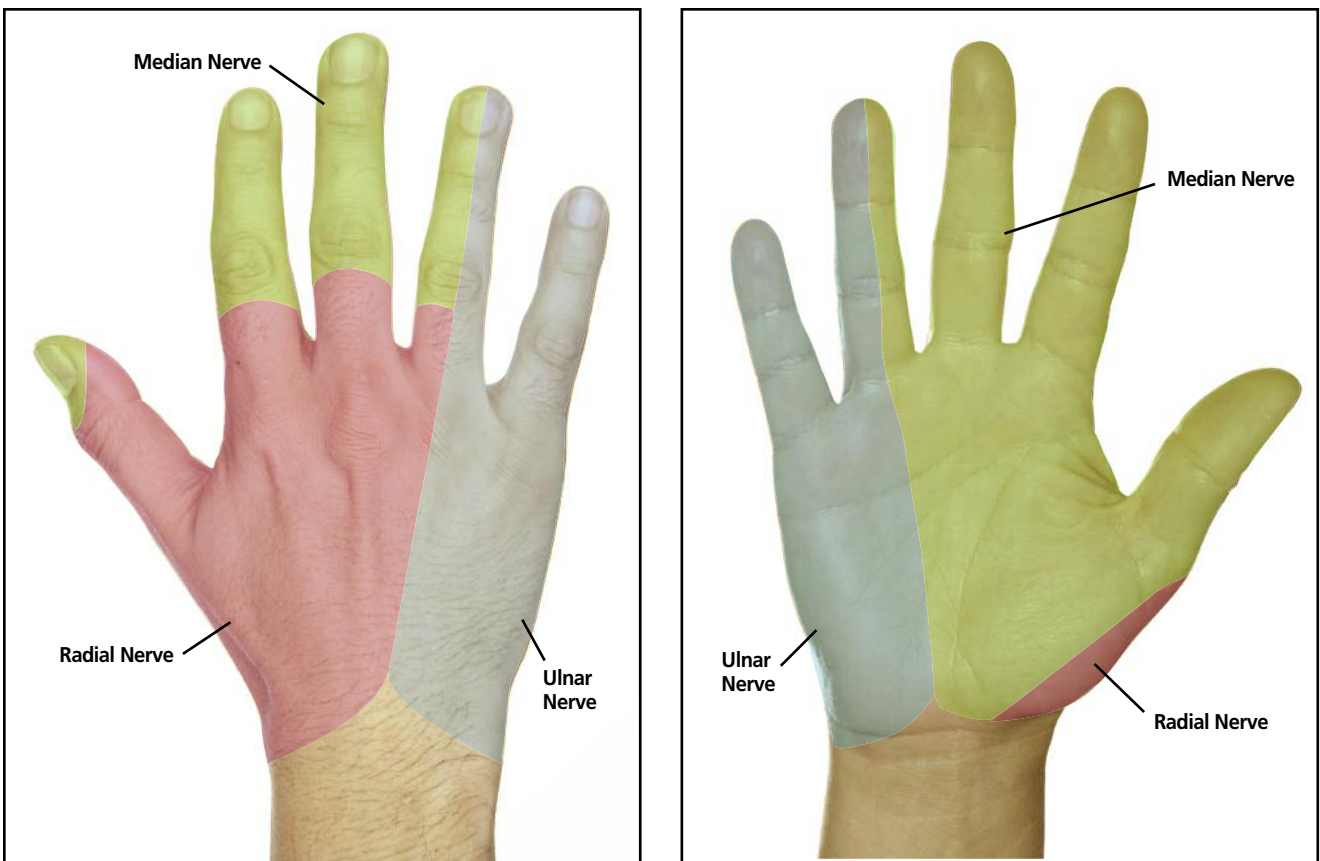


Figure 4. Symptoms of paresthesia in carpal tunnel syndrome in the typical distribution of the median nerve.

ultrasonography as a first-line confirmatory test in diagnosing CTS. In this test, cross-sectional areas of the median nerve are measured in healthy patients and in CTS patients. However, further studies are still warranted on this diagnostic test. Lastly, these imaging studies may be useful in detecting lesions, such as bifid median nerves and synovitis, though these studies are associated with a relatively higher cost.

Osteopathic Structural Examination

A thorough understanding of upper limb anatomy plays a critical role in elucidating the etiology of CTS. Osteopathic structural examination serves to detect somatic dysfunctions, defined as altered or impaired body structures that involve skeletal, arthrodial, myofascial, vascular, lymphatic, and neural components. Diagnostic criteria are tenderness, asymmetry, restriction, and tissue texture changes, or TART.⁴² For patients with CTS, osteopathic structural examination would focus on somatic dysfunction in the hand, wrist, and upper limb. Palpatory examination should focus on the following anatomic components:

■ **Carpal Tunnel**—First, the carpal tunnel contents should be

examined using modified range-of-motion procedures reported by Sucher,⁴³ which were designed for the assessment of somatic dysfunction. Restrictions of motion are graded from 0 to 5 according to the following scale: 0, no restriction; 1, mild restriction; 2, moderate restriction; 3, moderate to marked restriction; 4, marked restriction; and 5, extremely marked restriction.⁴³ Patients are assessed in the seated position with the wrist flexed to approximately 90° (Figure 5 and Figure 6).

■ **Carpal and Metacarpal Bones**—Second, the carpal and metacarpal bones should be examined by assessing for restriction of motion. Dislocation or displacement of the lunate bone can compress the median nerve and lead to CTS; attention should focus on this carpal bone. Additionally, the lunate bone is surrounded by other carpal bones, and the TCL, which contributes to the tunnel, is attached to 4 carpal bones (ie, hamate, pisiform, scaphoid, and trapezium). Hence, each carpal bone should be evaluated because any degree of displacement can affect carpal tunnel anatomy and may therefore increase intratunnel pressure. Subsequently, as a result of carpal bone articulation with the metacarpals, assessment of the metacarpal bones must be included in the examination. These bones articulate with

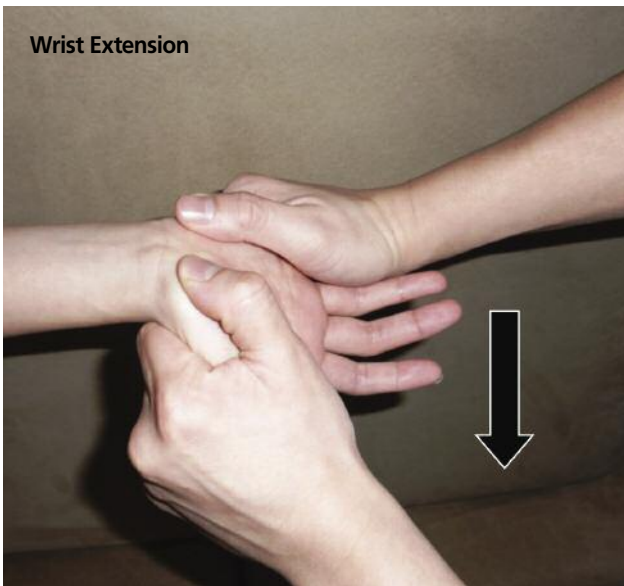

Figure 5. The physician induces wrist extension and flexion to evaluate for restriction in passive range of motion, observing the patient for signs of discomfort or pain in these positions. The physician compares the findings in the affected wrist with those in the unaffected wrist to note differences in range of motion.

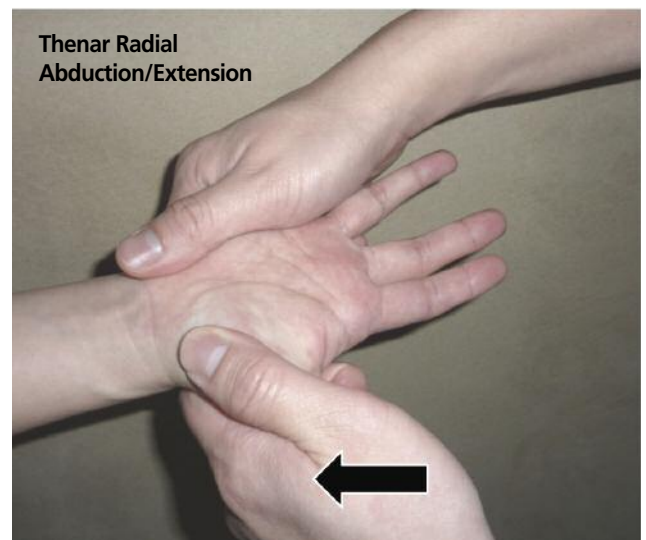
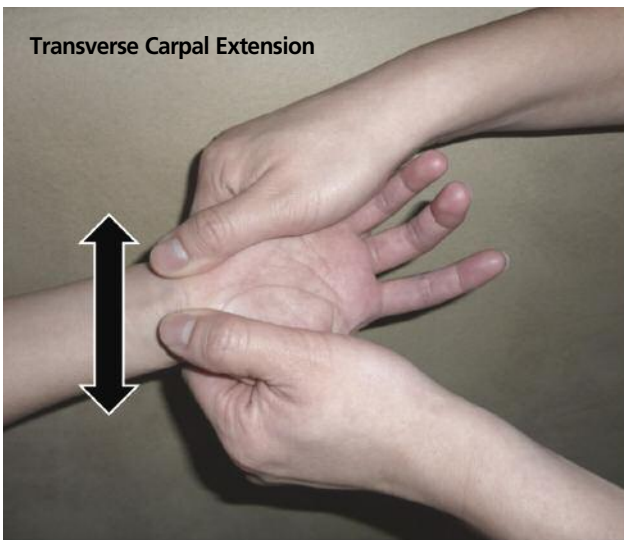


Figure 6. The physician induces transverse extension of the carpal tunnel and thenar radial abduction/extension to assess for restriction in passive range of motion. The physician compares the findings in the affected wrist with those in the unaffected wrist to note differences in range of motion.

the distal carpal bones, and any metacarpal restriction can thus influence carpal bone alignment.

- **Distal Radius and Ulna**—Third, because the distal radius and ulna also influence carpal bone position and motion, particularly the lunate bone, evaluation of the radiocarpal and ulnocarpal joints must be performed (*Figure 7* and *Figure 8*).
- **Anterior Forearm Muscles and Interosseous Membrane**—Fourth, the anterior forearm muscles and interosseous mem-

brane stabilize the radius and ulna in the forearm. Dysfunction in these supporting tissues affects the position of the radius and ulna, which alters the anatomic position of the carpal bones and tendons traversing the carpal tunnel. Palpation of the interosseous membrane and anterior forearm muscles may reveal areas of a taut fibrous band, pain, or ease-bind tissue elasticity asymmetry.

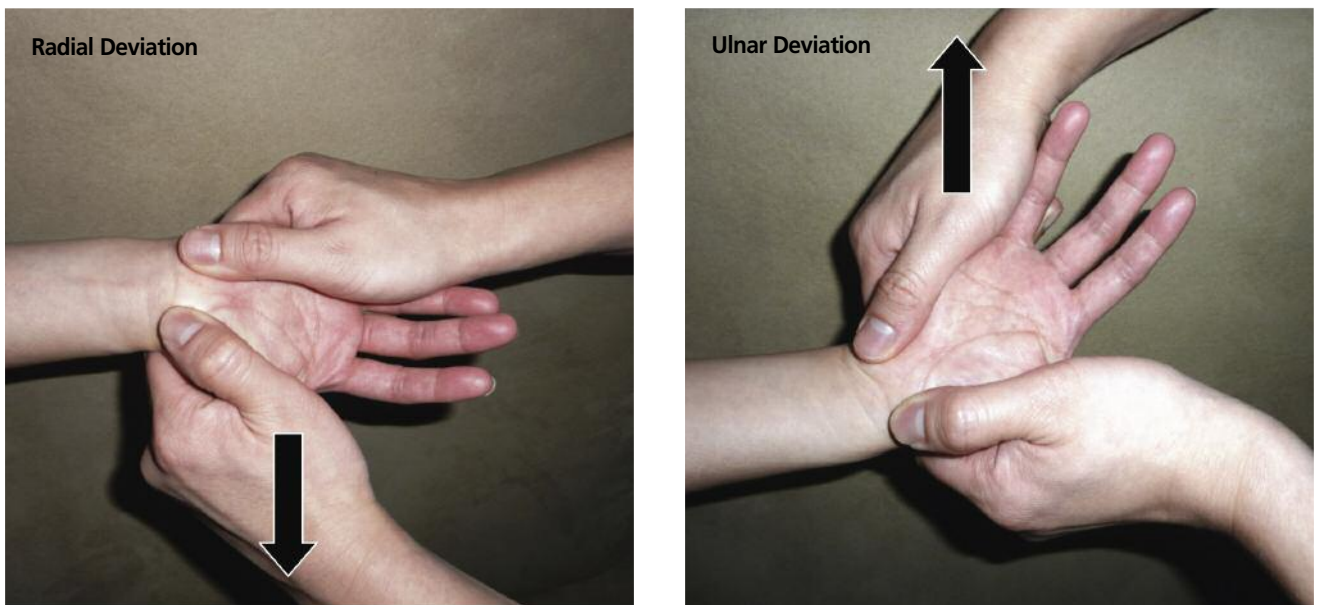


Figure 7. The physician induces radial deviation (lateral abduction) and ulnar deviation (lateral adduction) at the wrist to assess for restrictions in range of motion. The physician compares the findings in the affected wrist with those in the unaffected wrist to note any difference.

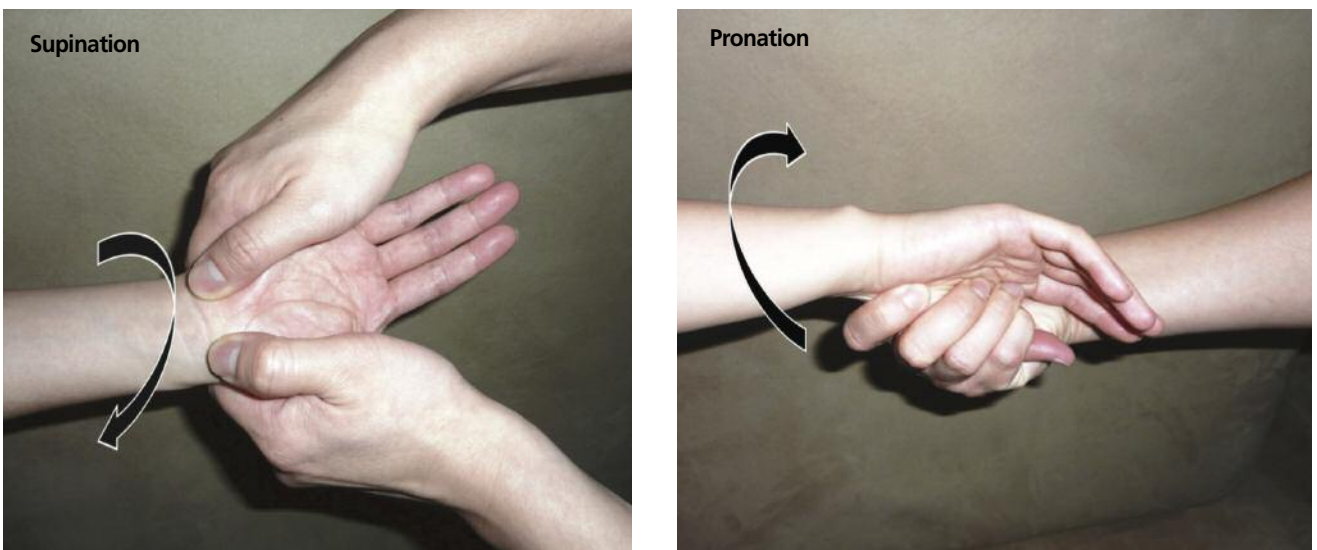


Figure 8. The physician induces supination and pronation at the wrist to assess for restricted passive range of motion. The physician compares the findings in the affected wrist with those in the unaffected wrist.

The osteopathic palpatory findings, imaging findings, and results of electrodiagnostic studies should be correlated with clinical symptoms and subjective patient reports of suspicious pain, tenderness, paresthesia, or restrictions in active range of motion to more definitively diagnose CTS.

Conventional Management

Standard treatment for patients with CTS includes rest, wrist immobilization with a splint, avoidance of provoca-

tive activities, and modification of physical behaviors in conjunction with as-needed nonsteroidal anti-inflammatory drugs. Conservative therapies are effective in approximately 80% of patients; however, symptoms can recur in up to 80% of these patients after 1 year.⁴⁴ In another study, after failure of conservative therapy, the use of local anesthetics and corticosteroid injections for the management of CTS resulted in improved symptoms in 56% to 73% of patients.⁴⁵ If these treatments prove ineffective, surgical

techniques to relieve carpal tunnel pressure may be indicated, and consultation with an appropriate surgeon may be warranted.

Incision of the TCL increases the volume of the carpal canal and has been postulated to alter the kinematics of the carpus, but this procedure includes the risk of bowstringing the flexor tendons, which can compromise grip strength.⁶ Complications of surgical procedures are low, approximately 1% to 2%, and include nerve, tendon, and blood vessel injury, infection, scarring, chronic tenderness of the surgical site, pain, hematoma, complex regional pain syndrome, and the potential need for additional surgical procedures.^{46,47}

Osteopathic Manipulative Treatment

When osteopathic structural examination reveals somatic dysfunction associated with CTS, osteopathic manipulative treatment may be used to manage the somatic dysfunction. Specifically, OMT may be used to stretch soft tissues, release tissue adhesions, eliminate restricted motion of carpal and metacarpal bones, increase the length of the TCL to enlarge the carpal tunnel and lower intratunnel

pressure transmitted to the median nerve, increase range of motion, strengthen muscles, and reduce edema. Resultant improvements in circulation and joint function will allow for normalization of nerve function. As described in the following paragraphs, several techniques can be used to manage somatic dysfunction in various parts of the wrist and hand that are associated with CTS.

Wrist Retinaculum

Myofascial release technique—The physician places his or her fourth and fifth digits of both hands between the patient's fourth and fifth digits and first and second digits of the palmar surface⁴⁸ (Figure 9A). Dorsiflexion of the patient's wrist is introduced, and the physician's thumbs overlie the lateral and medial attachments of the wrist flexor retinaculum (transverse carpal ligament) (Figure 9B). Transverse distraction is applied to the retinaculum by using a 3-point or 4-point bending technique, with 2 points ventral and 1 to 2 points dorsal until relaxation of the soft tissue or release of the restriction is attained (Figure 9C). In cases in which dorsiflexion elicits CTS symptoms, myofascial release can be performed without dorsiflexion of the wrist.

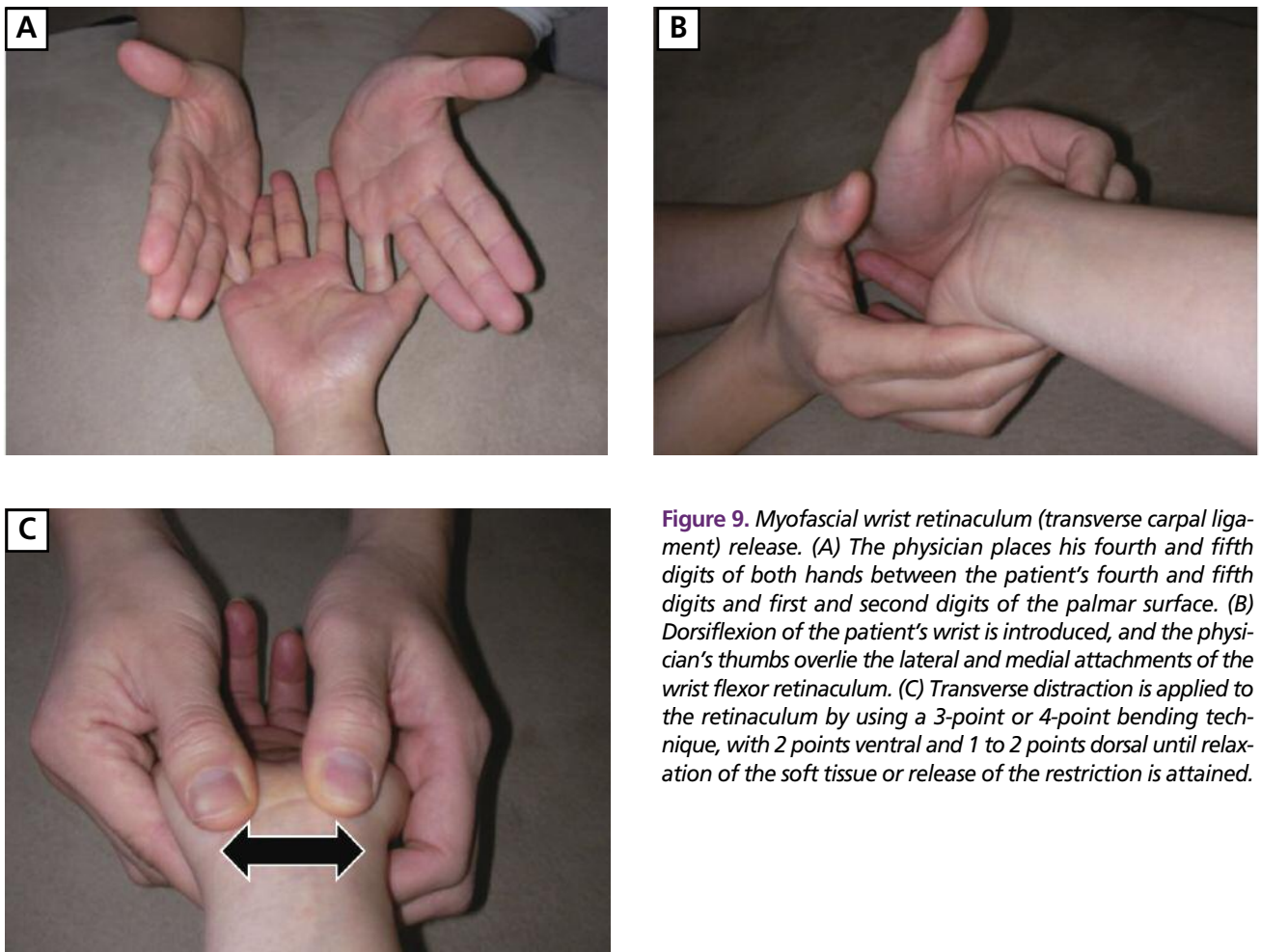


Figure 9. Myofascial wrist retinaculum (transverse carpal ligament) release. (A) The physician places his fourth and fifth digits of both hands between the patient's fourth and fifth digits and first and second digits of the palmar surface. (B) Dorsiflexion of the patient's wrist is introduced, and the physician's thumbs overlie the lateral and medial attachments of the wrist flexor retinaculum. (C) Transverse distraction is applied to the retinaculum by using a 3-point or 4-point bending technique, with 2 points ventral and 1 to 2 points dorsal until relaxation of the soft tissue or release of the restriction is attained.

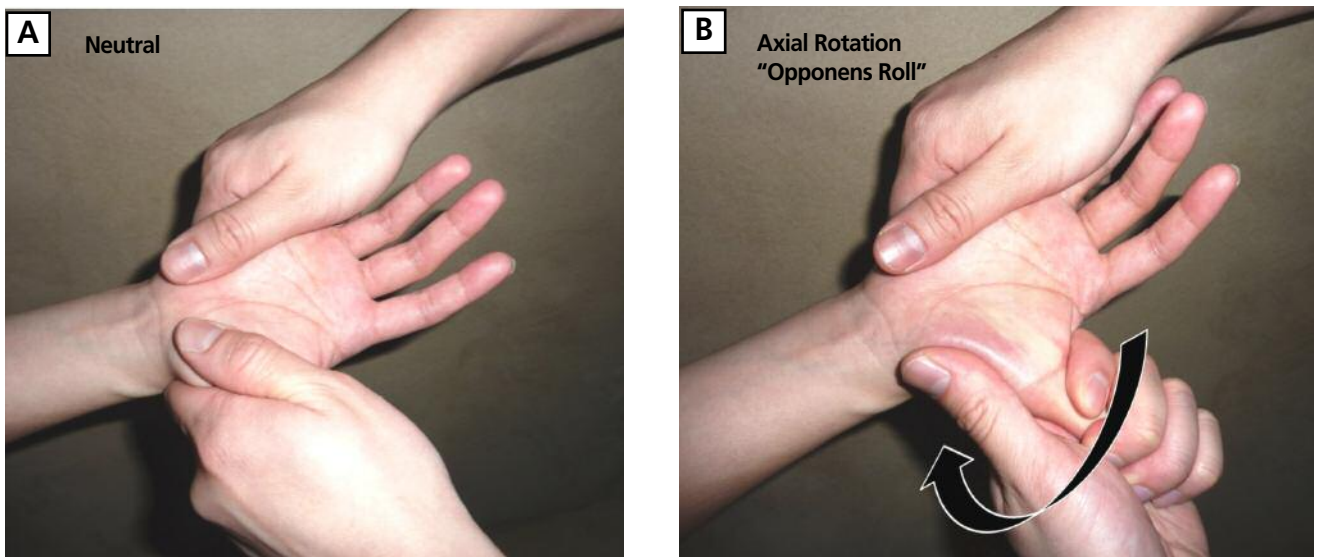


Figure 10. *Thenar, carpal ligament release (Opponens roll maneuver).* (A) *The physician grasps the patient's hypothenar and thenar region* (B) *The physician gradually pulls the thenar area laterally, while also moving the thumb into extension to create traction.*

Thenar and Carpal Ligament

Opponens roll maneuver—This maneuver⁴³ involves lateral and axial rotation of the thumb, which creates substantial traction on the attachment of the opponens pollicis muscle. The muscle originates from the transverse carpal ligament and tubercle of the trapezium bone. This maneuver stretches the muscle and transverse carpal ligament, releasing pressure within the carpal tunnel and unloading pressure on the median nerve.⁴³

The physician performs this technique by grasping the hypothenar region of the patient and then using his or her other hand to grasp the patient's thenar area. The physician gradually pulls the patient's thenar area laterally while simultaneously moving the thumb into extension to create traction (Figure 10). In addition, the abductor pollicis brevis is extended and abducted. A progressive phase of stretch further extends and abducts the opponens and abductor muscles. This technique is especially useful as patients can be educated on how to self-perform the opponens roll maneuver by using the contralateral hand to grasp and extend the thumb.

Carpal Bone

High-velocity, low-amplitude technique (mobilization with impulse)—The physician's hands grasp the patient's hand and wrist^{48,49} with the thumb contacting the dorsal aspect of the dysfunctional carpal bone (Figure 11A). The physician uses the thumb of the other hand to reinforce the dysfunctional carpal bone while the index fingers grasp the anterior aspect of the carpal bones (Figure 11B). A dorsiflexion barrier is then engaged, and the physician applies

a mobilization with impulse thrust moving the patient's wrist toward the floor in a whipping motion (Figure 11C). A palmar flexion barrier is then engaged, and the physician applies a mobilization with impulse thrust by moving the patient's wrist in the opposite direction (Figure 11D).

Metacarpophalangeal Joint

High-velocity, low-amplitude technique (mobilization with impulse)—The physician grasps an individual phalanx with his or her index fingers and palm⁴⁸ (Figure 12A). Traction is then applied to the metacarpophalangeal joint, and a mobilization with impulse thrust is applied distally in an axial manner. The same technique is applied to the remaining untreated metacarpophalangeal joints.

Carpometacarpal Joint

High-velocity, low-amplitude technique (mobilization with impulse)—With the physician's thumb contacting the dorsal aspect of an individual metacarpal, the index fingers grasp the dorsal aspect of the metacarpal⁴⁸ (Figure 12B). Mobilization occurs by gently applying a downward force with the thumb until a barrier is engaged and subsequently applying an upward force with the index fingers. The remaining untreated metacarpals are then mobilized in the same fashion.

Radius and Ulna

Because the distal radius and ulna are in contact with the proximal carpal bones that influence motion at the radiocarpal, ulnocarpal, and radioulnar joints, management of the radius and ulna is important in treating patients with

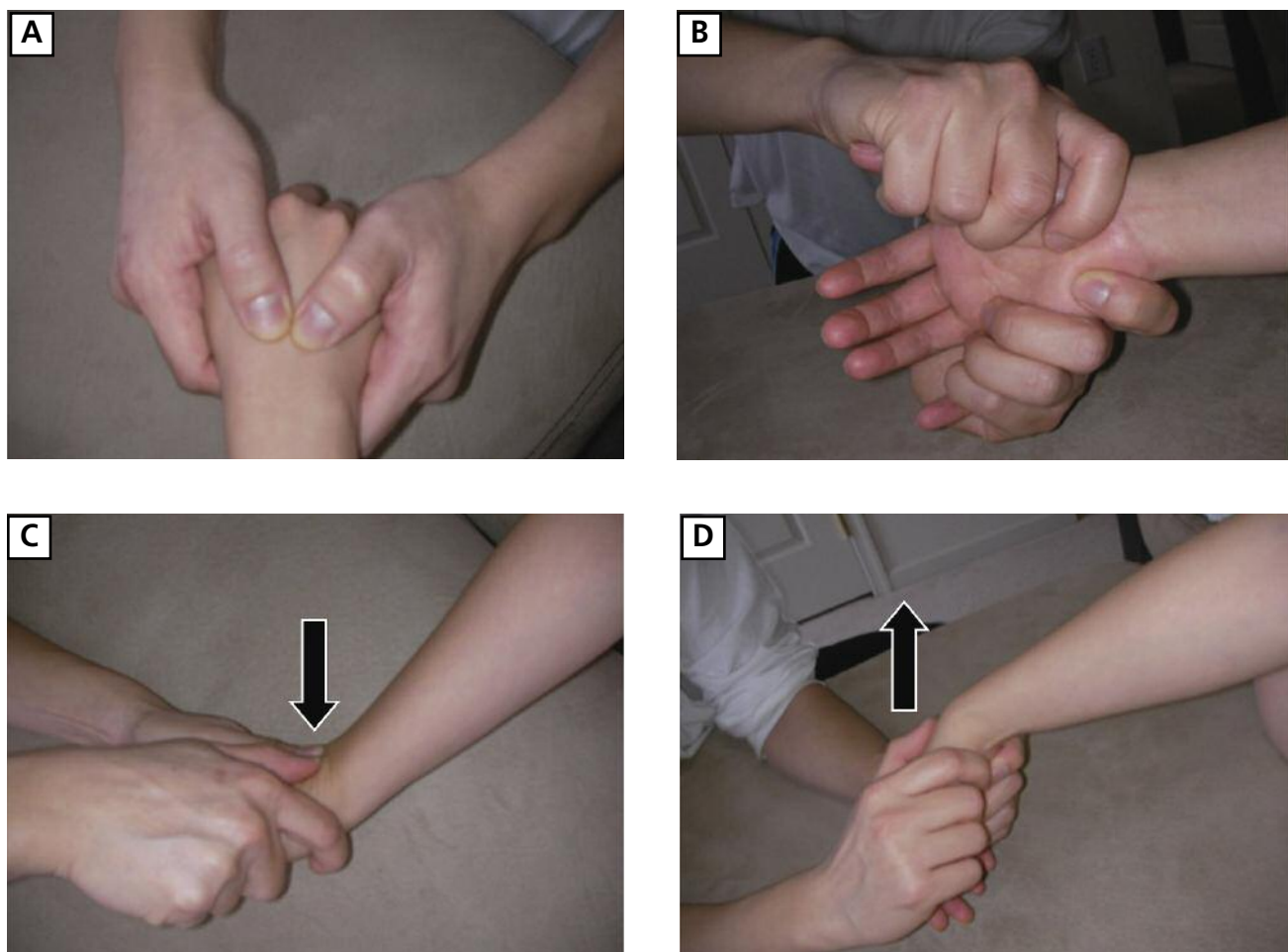


Figure 11. Carpal bone high-velocity, low-amplitude technique. (A) The physician's hands grasp the patient's hand and wrist. (B) The physician's index fingers grasp the anterior aspect of the carpal bones. (C) A dorsiflexion barrier is engaged, and the physician applies a mobilization with impulse thrust moving the patient's wrist toward the floor in a whipping motion. (D) A palmar flexion barrier is engaged, and the physician applies a mobilization with impulse thrust by moving the patient's wrist in the opposite direction.

CTS. The most common dysfunction is that of the radial head, resulting in pronation or supination dysfunction.

High-velocity, low-amplitude technique (mobilization with impulse) for posterior radial head dysfunction (pronation dysfunction)—The physician places his or her thenar eminence on the patient's posterior radial head using his or her index fingers to grasp the patient's medial elbow.⁴⁸ The patient's forearm is then rotated into supination until the restrictive barrier is reached. The forearm is then extended and a mobilization with impulse thrust is applied with the thenar eminence.

Muscle energy technique for pronation and supination dysfunctions—To manage pronation dysfunction, the physician holds the patient's hand in a handshake position while the palm of the free hand contacts the posterolateral

aspect of the radial head to be treated⁴⁸ (Figure 13A). Supination is applied to the patient's forearm until a restrictive barrier is reached. The patient then attempts to pronate his or her forearm while the physician applies a counterforce for 3 to 5 seconds. The contraction is then relaxed and the patient is supinated to a new restrictive barrier, and again the patient pronates his or her forearm while the physician applies a similar counterforce. These steps are repeated 3 to 5 times.

For supination dysfunction, the physician holds the patient's hand in a handshake position while the palm of the free hand contacts the posterolateral aspect of the radial head (Figure 13B). Pronation is applied to the patient's forearm until a restrictive barrier is reached. The patient then attempts to supinate his or her forearm while the physician applies a counterforce for 3 to 5 seconds. The contraction is then relaxed, the patient is pronated to a new

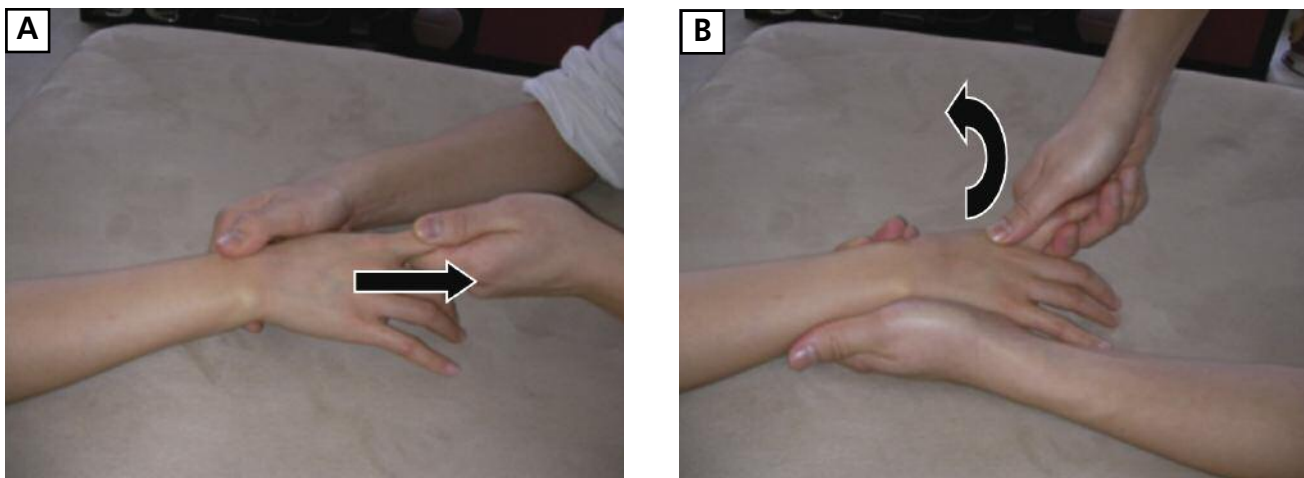


Figure 12. Metacarpophalangeal joint and carpometacarpal joint mobilization. (A) The physician grasps an individual phalanx with his or her index fingers and palm. Traction is then applied to the metacarpophalangeal joint and a mobilization with impulse thrust is applied distally in an axial manner. (B) With the practitioner's thumb contacting the dorsal aspect of an individual metacarpal, the index fingers grasp the dorsal aspect of the metacarpal. Mobilization occurs by gently applying a downward force with the thumb until a barrier is engaged and subsequently applying an upward force with the index fingers.

restrictive barrier, and again the patient supinates his or her forearm while the physician applies a counterforce. These steps are repeated 3 to 5 times.

Interosseous Membrane and Forearm Muscle

Myofascial release technique (bilateral thumb pressure technique)—The physician's 2 hands grasp the patient's distal forearm with the thumbs contacting the anterior aspect of the forearm muscles and interosseous membrane while the index fingers grasp the posterior aspect of the forearm⁴⁹ (Figure 14A). The physician's thumbs exert a gentle force ventrally to engage the soft tissues cephalad

and laterally until a barrier of tissue motion is reached (Figure 14B). Continuing proximally on the forearm while holding a stretch for 3 to 5 seconds, the grasp is slowly released and gentle, rhythmic, sustained pressure is applied. The same bilateral thumb pressure technique is then applied to the posterior aspect of the forearm. An alternative method can be performed by placing the thumbs over the anterior aspect of the forearm and applying a gentle pressure and circling motion (clockwise and counter-clockwise) to the forearm. Treatment of this area will alleviate tension of the musculature between the radius and ulna.

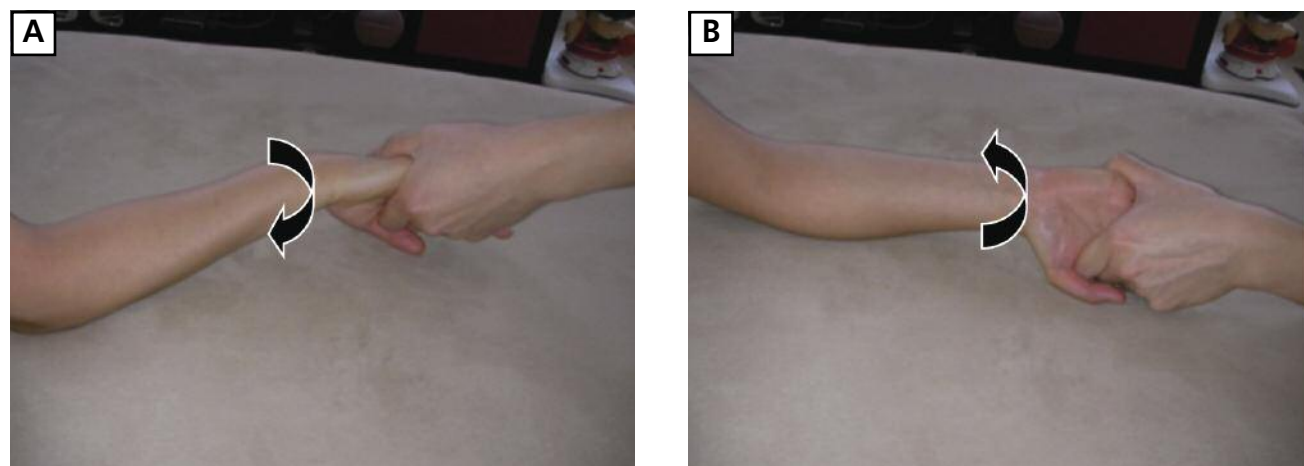


Figure 13. Supination dysfunction and pronation dysfunction muscle energy technique. The physician holds the patient's hand in a handshake position while the palm of the free hand contacts the posterolateral aspect of the radial head to be treated. Supination (A) and pronation (B) are applied to the patient's forearm until a restrictive barrier is reached.

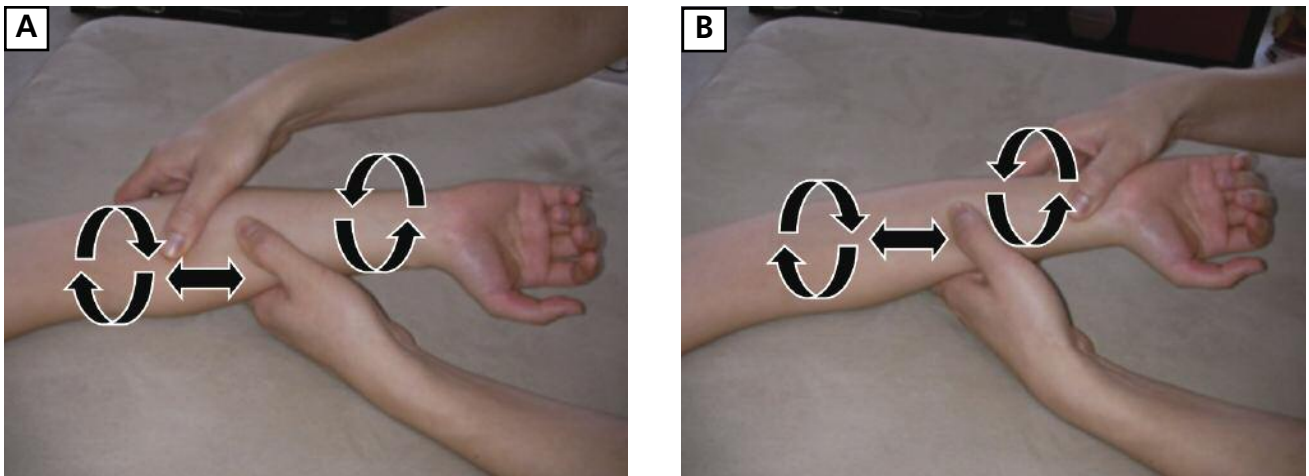


Figure 14. Interosseous membrane and forearm muscles myofascial release (bilateral thumb pressure technique). (A) The physician's 2 hands grasp the patient's distal forearm with the thumbs contacting the anterior aspect of the forearm muscles and interosseous membrane while the index fingers grasp the posterior aspect of the forearm. (B) The physician's thumbs exert a gentle force ventrally to engage the soft tissues cephalad and laterally until a barrier of tissue motion is reached.

Clinical Efficacy of OMM on CTS

Multiple published studies have outlined the clinical effectiveness of OMT on patients diagnosed with CTS.^{43,50-52} Sucher⁴³ demonstrated that osteopathic palpatory diagnosis in 20 patients with carpal tunnel syndrome revealed at least moderate restriction (grade 2), compared to 20 healthy, symptom-free patients with no to mild restriction (grade 0-1). In the same study, 16 patients with CTS who had at least a grade 2 restriction and who were treated with OMT experienced improved range of motion and decreased symptoms of CTS.⁴³ Results of nerve conduction studies improved within 1 to 3 months.

In another study, Sucher⁵² demonstrated that after OMT, magnetic resonance imaging results showed the anteroposterior and transverse dimensions of the carpal canal to be substantially increased and reported a concomitant improvement with subsequent nerve conduction studies. Additional research efforts by Sucher et al⁵³ showed that OMT widens the transverse carpal arch and lengthens the transverse carpal ligament in cadaver studies.

Questions are raised, however, regarding the experimental design and lack of statistical analysis and power of Sucher's studies because of the small sample sizes. Also, inclusion and exclusion criteria were not outlined in these studies, which limits the studies' generalizability. On the other hand, studies with stronger designs have supported Sucher's findings; Tal-Akabi and Rushton⁵⁴ developed a structured research method and demonstrated that carpal bone mobilization improved patients' symptoms with satisfactory results.

Comment

As early as the mid-19th century, Paget⁵⁵ documented the use of neutral splints to treat patients with CTS. Since then, as the practice of medicine has matured and research efforts have increased, CTS treatment options have evolved into a spectrum of conservative, noninvasive methods and surgical techniques. Despite the continuous growth of knowledge and published literature, OMM for carpal tunnel syndrome may often be overlooked. Randomized clinical trials have demonstrated greater improvements in symptom severity and functional status in patients who were treated with surgical procedures than in those who were treated with conservative strategies.^{46,56} However, complications associated with surgical interventions can lead to morbidities, which may detract from their clinical efficacy.^{46,56}

Osteopathic manipulative medicine enables physicians to noninvasively diagnose and manage CTS. Diagnosis with OMM should not be considered a replacement for diagnosis with electrodiagnostic studies and other provocative tests. Rather, it should be viewed as an adjunct and extension to the physical examination. Osteopathic manipulative treatment techniques assist in relieving pressure in the carpal tunnel, stretching soft tissues, alleviating restricted metacarpal and carpal bones, increasing the length of the TCL to enlarge the carpal tunnel, increasing range of motion, strengthening muscles, and removing excess fluid, all of which can result in improvements in circulation and nerve function. Hunter et al⁵⁷ and Amadio⁵⁸ suggested that manipulation can also reduce adhesions produced as a result of inflammatory sequelae of the disorder.

In addition to being used to treat patients with CTS,

OMM can help monitor the progression of CTS and patients' response to treatment, minimizing the need for serial electrodiagnostic studies, steroid injections, and surgical procedures, which can ultimately reduce overall treatment cost. Further, a treatment plan that uses OMM in addition to exercise and stretching activities can prevent progression of CTS and can reduce morbidity.

Despite multiple studies documenting the effectiveness of OMM for CTS, further research is warranted. Future studies should investigate nonoperative treatments such as splinting and nonsteroidal anti-inflammatory drugs in combination with OMM, as well as steroid injection therapies in conjunction with OMM to demonstrate the effectiveness of these combination regimens. Additionally, studies with larger samples will reveal whether a correlation between repetitive stress injury and somatic dysfunction exists and will determine causality, if it exists. Measurements of nerve conduction studies, range of motion, somatic dysfunction, sensory examination, and motor strength can be integrated in future investigations to demonstrate the role of OMM in the treatment of patients with CTS and to measure the degree to which nerve function and wrist-hand performance of patients improves.

Conclusion

The application of OMM is generally underused and overlooked in the management of CTS. Although there are multiple causes of CTS, using OMM (ie, osteopathic structural examination and OMT) in the diagnosis and management of CTS may ultimately prevent or delay surgical intervention in patients with this condition.

Acknowledgments

The authors thank Floria Siu for being our hand model and for providing technical support for this article.

References

- Latinovic R, Gulliford MC, Hughes RA. Incidence of common compressive neuropathies in primary care. *J Neurol Neurosurg Psychiatry*. 2006;77(2):263-265.
- Feuerstein M, Miller VL, Burrell LM, Berger R. Occupational upper extremity disorders in the federal workforce: prevalence, health care expenditures, and patterns of work disability. *J Occup Environ Med*. 1998;40(6):546-555.
- Patterson JD, Simmons BP. Outcomes assessment in carpal tunnel syndrome. *Hand Clin*. 2002;18(2):359-363.
- Atroshi I, Gummesson C, Johnsson R, Ornstein E, Ranstam J, Rosén I. Prevalence of carpal tunnel syndrome in a general population. *JAMA*. 1999;282(2):153-158.
- Papanicolaou GD, McCabe SJ, Firrell J. The prevalence and characteristics of nerve compression symptoms in the general population. *J Hand Surg Am*. 2001;26(3):460-466.
- Cobb TK, Dalley BK, Posteraro RH, Lewis RC. Anatomy of the flexor retinaculum. *J Hand Surg Am*. 1993;18(1):91-99.
- von Schroeder HP, Botte MJ. Carpal tunnel syndrome. *Hand Clin*. 1996;12(4):643-655.
- Stevens JC, Beard CM, O'Fallon WM, Kurland LT. Conditions associated with carpal tunnel syndrome. *Mayo Clin Proc*. 1992;67(6):541-548.
- Gelberman RH, Hergenroeder PT, Hargens AR, Lundborg GN, Akeson WH. The

- carpal tunnel syndrome: a study of carpal canal pressures. *J Bone Joint Surg Am*. 1981;63(3):380-383.
- Rettig AC. Athletic injuries of the wrist and hand: part I—traumatic injuries of the wrist. *Am J Sports Med*. 2003;31:1038-1048.
- Kerrigan JJ, Bertoni JM, Jaeger SH. Ganglion cysts and carpal tunnel syndrome. *J Hand Surg Am*. 1988;13:763-765.
- Lundborg G, Gelberman RH, Minteer-Convery M, Lee YF, Hargens AR. Median nerve compression in the carpal tunnel: functional response to experimentally induced controlled pressure. *J Hand Surg Am*. 1982;7(3):252-259.
- Shiri R, Miranda H, Heliövaara M, Viikari-Juntura E. Physical work load factors and carpal tunnel syndrome: a population-based study. *Occup Environ Med*. 2009;66(6):368-373.
- Fung BK, Chan KY, Lam LY, et al. Study of wrist posture, loading and repetitive motion as risk factors for developing carpal tunnel syndrome. *Hand Surg*. 2007;12(1):13-18.
- Keir PJ, Rempel DM. Pathomechanics of peripheral nerve loading: evidence in carpal tunnel syndrome. *J Hand Ther*. 2005;18(2):259-269.
- Kerwin G, Williams CS, Seiler JG 3rd. The pathophysiology of carpal tunnel syndrome. *Hand Clin*. 1996;12(2):243-251.
- Lundborg G, Dahlin LB. The pathophysiology of nerve compression. *Hand Clin*. 1992;8(2):215-227.
- Rempel D, Dahlin L, Lundborg G. Pathophysiology of nerve compression syndromes: response of peripheral nerves to loading. *J Bone Joint Surg Am*. 1999;81(11):1600-1610.
- Pease WS, Cunningham ML, Walsh WE, Johnson EW. Determining neurapraxia in carpal tunnel syndrome. *Am J Phys Med Rehabil*. 1988;67(3):117-119.
- Sabini R, Vasishta D. Valleix phenomenon: an under recognized symptom in carpal tunnel syndrome, often misdiagnosed as cervical radiculopathy: a case report [poster 90]. *Arch Phys Med Rehabil*. 2008;89(11):e48-e49. doi:10.1016/j.apmr.2008.09.119.
- Rodriguez-Niedenführ M, Vazquez T, Parkin I, Logan B, Sañudo JR. Martin-Gruber anastomosis revisited. *Clin Anat*. 2002;15(2):129-134.
- Leibovic SJ, Hastings H II. Martin-Gruber revisited. *J Hand Surg Am*. 1992;17(1):47-53.
- Refaeian M, King JC, Dumitru D, Cuetter AC. Carpal tunnel syndrome and the Riche-Cannieu anastomosis: electrophysiologic findings. *Electromyogr Clin Neurophysiol*. 2001;41(6):377-382.
- Kuschner SH, Ebramzadeh E, Johnson D, Brien WW, Sherman R. Tinel's sign and Phalen's test in carpal tunnel syndrome. *Orthopedics*. 1992;15(11):1297-1302.
- Phalen GS. The diagnosis of carpal tunnel syndrome. *Cleve Clin Q*. 1968;35(1):1-6.
- D'Arcy CA, McGee S. The rational clinical examination: does this patient have carpal tunnel syndrome? *JAMA*. 2000;283(23):3110-3117.
- Katz JN, Stirrat CR, Larson MG, Fossel AH, Eaton HM, Liang MH. A self-administered hand symptom diagram for the diagnosis and epidemiologic study of carpal tunnel syndrome. *J Rheumatol*. 1990;17(11):1495-1498.
- Spindler HA, Dellon AL. Nerve conduction studies and sensibility testing in carpal tunnel syndrome. *J Hand Surg Am*. 1982;7(3):260-263.
- MacDermid JC, Wessel J. Clinical diagnosis of carpal tunnel syndrome: a systematic review. *J Hand Ther*. 2004;17(2):309-319.
- Viera AJ. Management of carpal tunnel syndrome. *Am Fam Physician*. 2003;68(2):265-272.
- Jablecki CK, Andary MT, Floeter MK, et al. Practice parameter: electrodiagnostic studies in carpal tunnel syndrome: report of the American Association of Electrodiagnostic Medicine, American Academy of Neurology, and the American Academy of Physical Medicine and Rehabilitation. *Neurology*. 2002;58(11):1589-1592.
- Robinson LR. Electrodiagnosis of carpal tunnel syndrome. *Phys Med Rehabil Clin N Am*. 2007;18(4):733-746.
- Kimura J. The carpal tunnel syndrome: localization of conduction abnormalities within the distal segment of the median nerve. *Brain*. 1979;102(3):619-635.
- Hamanaka I, Okutsu I, Shimizu K, Takatori Y, Ninomiya S. Evaluation of carpal

- canal pressure in carpal tunnel syndrome. *J Hand Surg Am.* 1995;20(5):848-854.
35. de Rijk MC, Vermeij FH, Suintjens M, van Doorn PA. Does a carpal tunnel syndrome predict an underlying disease? *J Neurol Neurosurg Psychiatry.* 2007;78(6):635-637.
36. Bindra RR, Evanoff BA, Chough LY, Cole RJ, Chow JC, Gelberman RH. The use of routine wrist radiography in the evaluation of patients with carpal tunnel syndrome. *J Hand Surg Am.* 1997;22(1):115-119.
37. Kleindienst A, Hamm B, Hildebrandt G, Klug N. Diagnosis and staging of carpal tunnel syndrome: comparison of magnetic resonance imaging and intra-operative findings. *Acta Neurochir (Wien).* 1996;138(2):228-233.
38. Kele H, Verheggen R, Bittermann HJ, Reimers CD. The potential value of ultrasonography in the evaluation of carpal tunnel syndrome. *Neurology.* 2003;61(3):389-391.
39. Klauser AS, Halpern EJ, De Zordo T, et al. Carpal tunnel syndrome assessment with US: value of additional cross-sectional area measurements of the median nerve in patients versus healthy volunteers. *Radiology.* 2009;250(1):171-177.
40. Karadağ YS, Karadağ O, Çiçekli E, et al. Severity of carpal tunnel syndrome assessed with high frequency ultrasonography. *Rheumatol Int.* 2010;30(6):761-765.
41. Fowler JR, Gaughan JP, Ilyas AM. The sensitivity and specificity of ultrasound for the diagnosis of carpal tunnel syndrome: a meta-analysis. *Clin Orthop Relat Res.* 2011;469(4):1089-1094.
42. Ward RC, ed. *Foundations for Osteopathic Medicine.* 2nd ed. Philadelphia, PA: Lippincott Williams & Wilkins; 2003.
43. Sucher BM. Palpatory diagnosis and manipulative management of carpal tunnel syndrome. *J Am Osteopath Assoc.* 1994;94(8):647-663.
44. Kanaan N, Sawaya RA. Carpal tunnel syndrome: modern diagnostic and management techniques. *Br J Gen Pract.* 2001;51(465):311-314.
45. Dammers JW, Roos Y, Veering MM, Vermeulen M. Injection with methylprednisolone in patients with the carpal tunnel syndrome: a randomised double blind trial testing three different doses. *J Neurol.* 2006;253(5):574-577.
46. Gerritsen AA, de Vet HC, Scholten RJ, Bertelsmann FW, de Krom MC, Bouter LM. Splinting vs surgery in the treatment of carpal tunnel syndrome: a randomized controlled trial. *JAMA.* 2002;288(10):1245-1251.
47. Boeckstyns ME, Sorensen AI. Does endoscopic carpal tunnel release have a higher rate of complications than open carpal tunnel release? an analysis of published series. *J Hand Surg Br.* 1999;24(1):9-15.
48. Greenman PE. *Principles of Manual Medicine.* 3rd ed. Philadelphia, PA: Lippincott Williams & Wilkins; 2003.
49. Nicholas AS, Nicholas EA. *Atlas of Osteopathic Techniques.* Philadelphia, PA: Lippincott Williams & Wilkins; 2008.
50. Sucher BM. Myofascial release of carpal tunnel syndrome. *J Am Osteopath Assoc.* 1993;93(1):92-94,100-101.
51. Sucher BM. Palpatory diagnosis and manipulative management of carpal tunnel syndrome: part 2—"double crush" and thoracic outlet syndrome. *J Am Osteopath Assoc.* 1995;95(8):471-479.
52. Sucher BM. Myofascial manipulative release of carpal tunnel syndrome: documentation with magnetic resonance imaging. *J Am Osteopath Assoc.* 1993;93(12):1273-1278.
53. Sucher BM, Hinrichs RN, Welcher RL, Quiroz LD, St Laurent BF, Morrison BJ. Manipulative treatment of carpal tunnel syndrome: biomechanical and osteopathic intervention to increase the length of the transverse carpal ligament: part 2—effect of sex differences and manipulative "priming." *J Am Osteopath Assoc.* 2005;105(3):135-143.
54. Tal-Akabi A, Rushton A. An investigation to compare the effectiveness of carpal bone mobilisation and neurodynamic mobilisation as methods of treatment for carpal tunnel syndrome. *Man Ther.* 2000;5(4):214-222.
55. Paget J. *Lectures on Surgical Pathology Delivered at the Royal College of Surgeons of England.* Philadelphia, PA: Lindsay and Blakiston; 1854.
56. Burke J, Buchberger DJ, Carey-Loghmani MT, Dougherty PE, Greco DS, Dishman JD. A pilot study comparing two manual therapy interventions for carpal tunnel syndrome. *J Manipulative Physiol Ther.* 2007;30(1):50-61.
57. Hunter JM, Read RL, Gray R. Carpal tunnel neuropathy caused by injury: reconstruction of the transverse carpal ligament for the complex carpal tunnel syndromes. *J Hand Ther.* 1993;6(2):145-151.
58. Amadio PC. The Mayo Clinic and carpal tunnel syndrome. *Mayo Clin Proc.* 1992;67(1):42-48.

JAOA Submissions: Online-Only Content

JAOA—*The Journal of the American Osteopathic Association* encourages authors to include additional online-only content (eg, videos, slides) with their manuscript submissions. Contact the JAOA's editorial assistant at jaoa@osteopathic.org for more information.